Ripetizione della toracoscopia (07.2011)

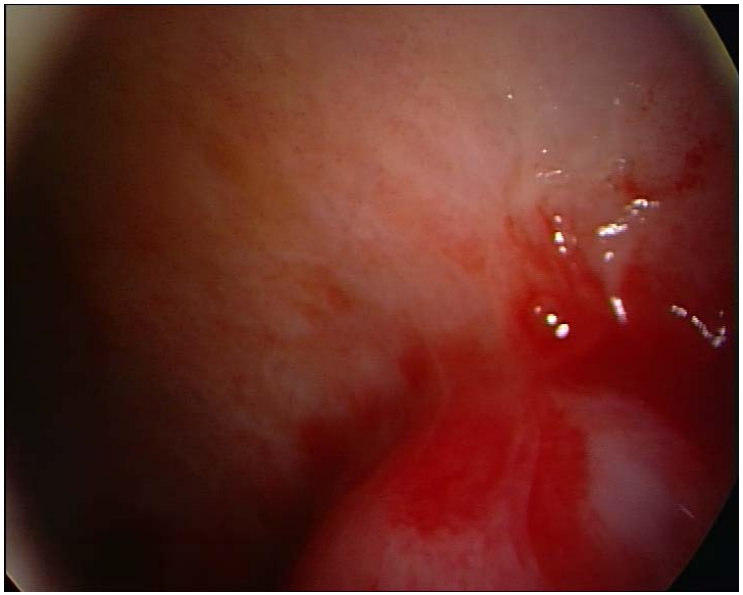

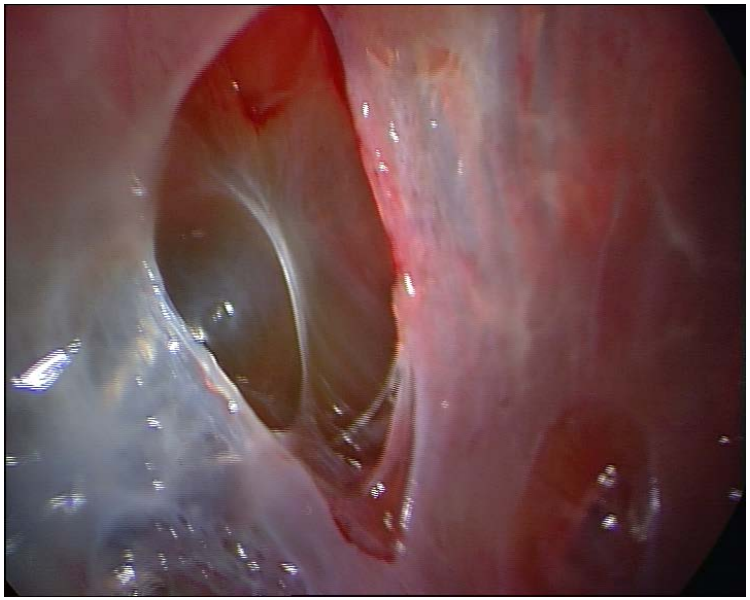

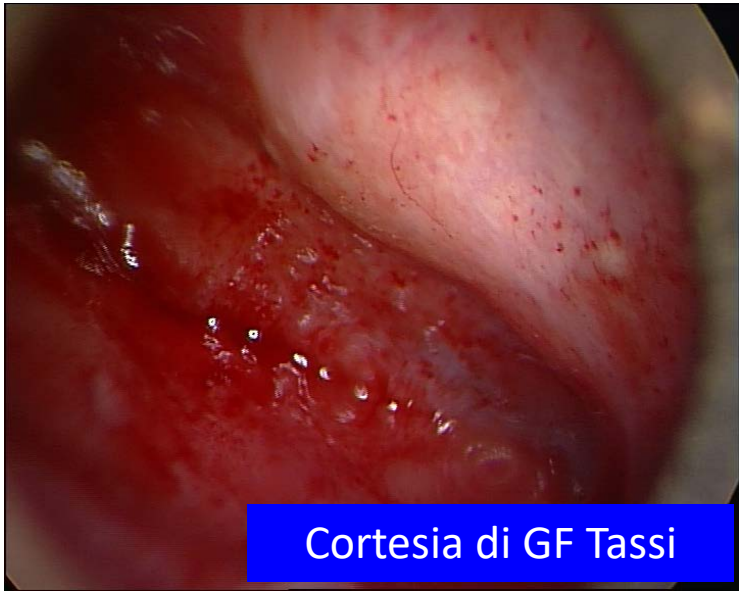

Cortesia di GF Tassi

Biopsia toracoscopica

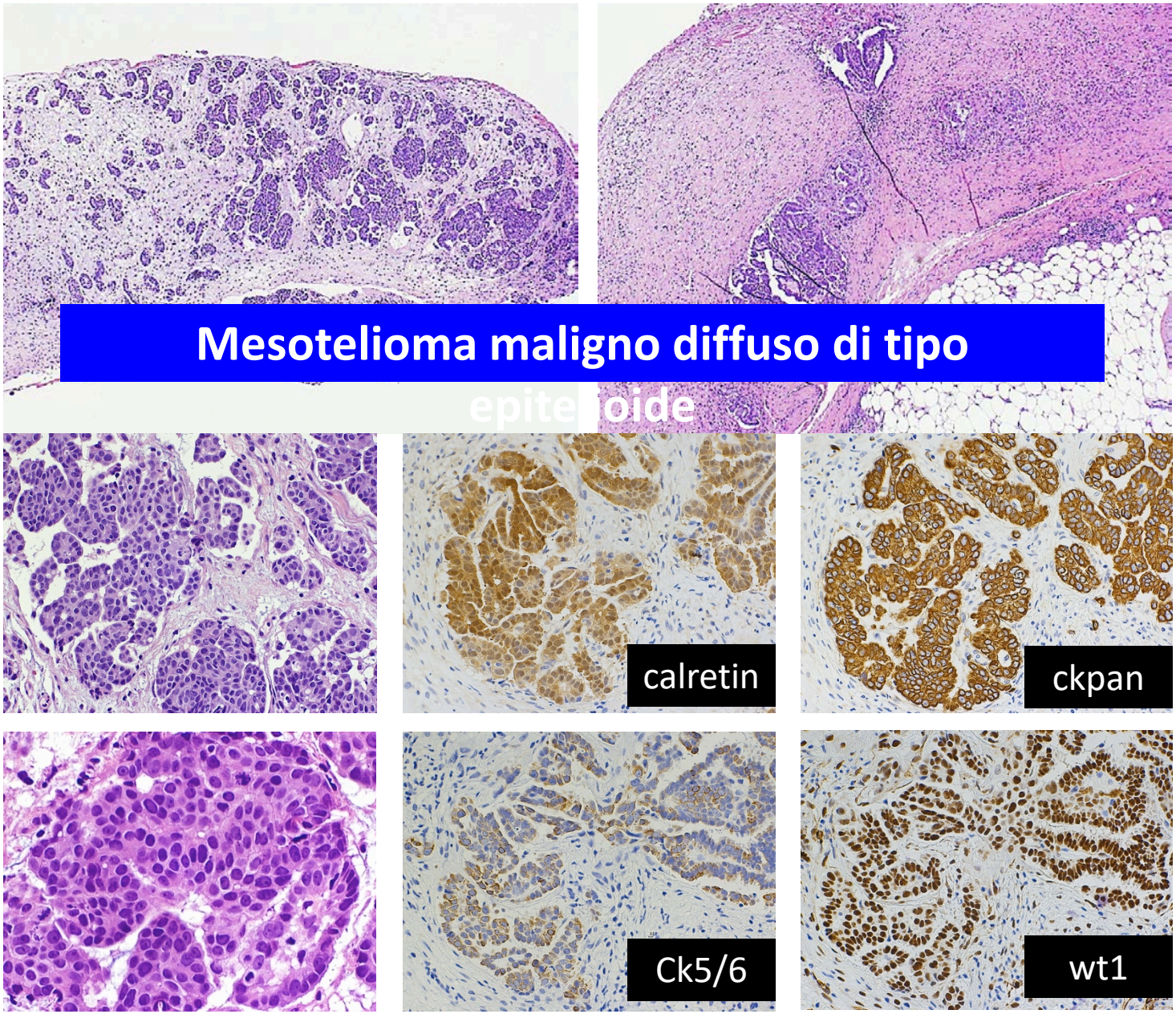

F 44 aa, pregresso ca mammario operato + RT (1997). Versamento pleurico, toracoscopia con biopsia

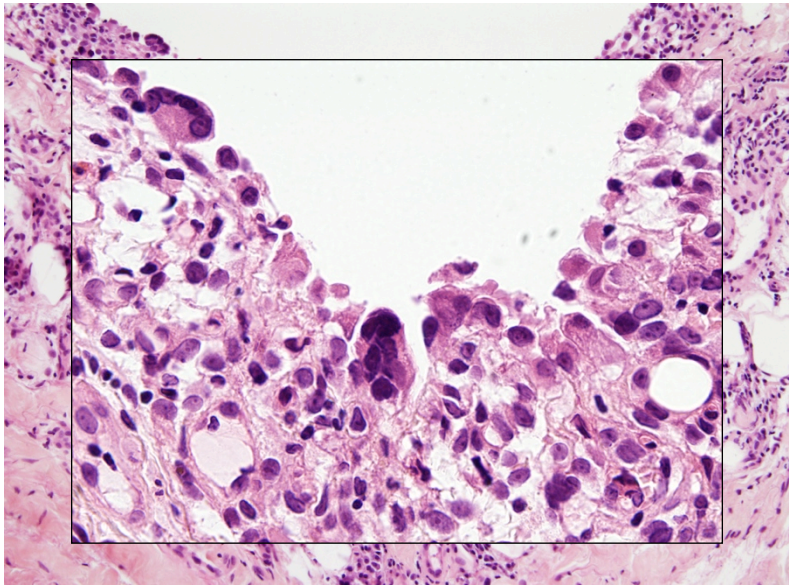

07.2007

PMA

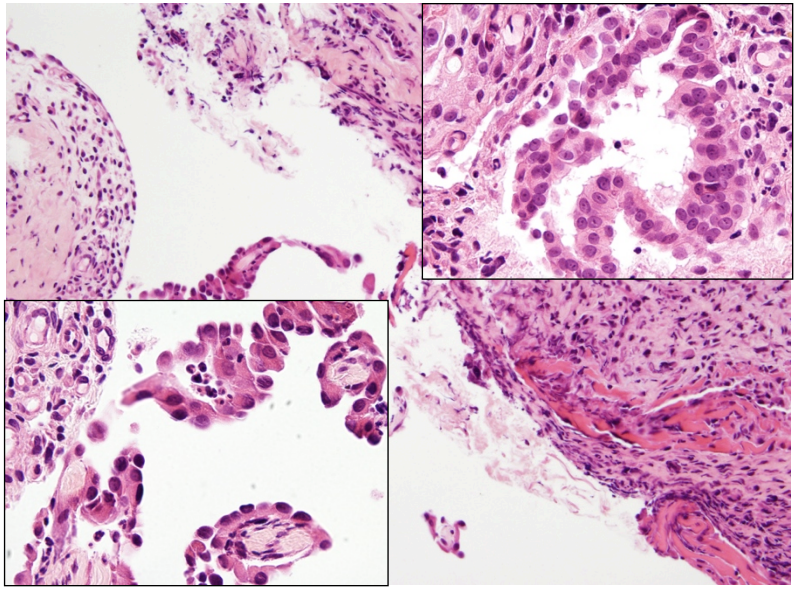

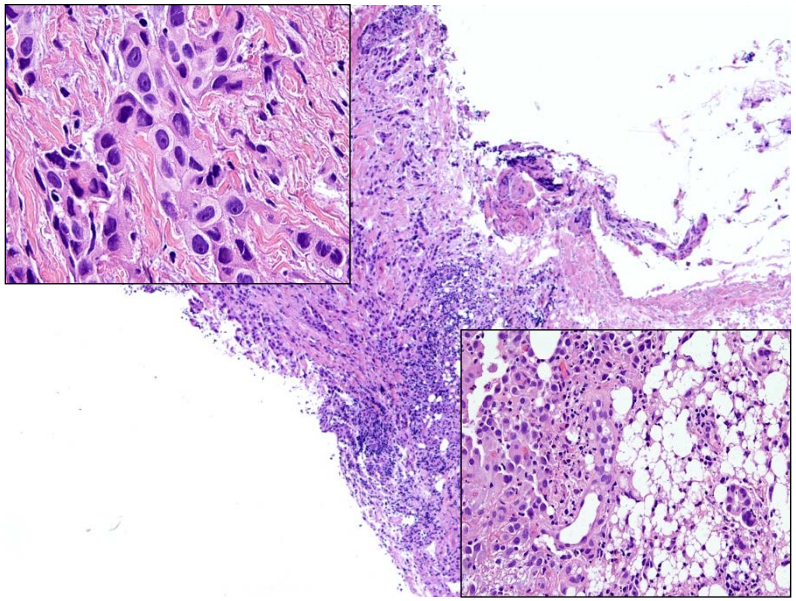

09.2008

MME

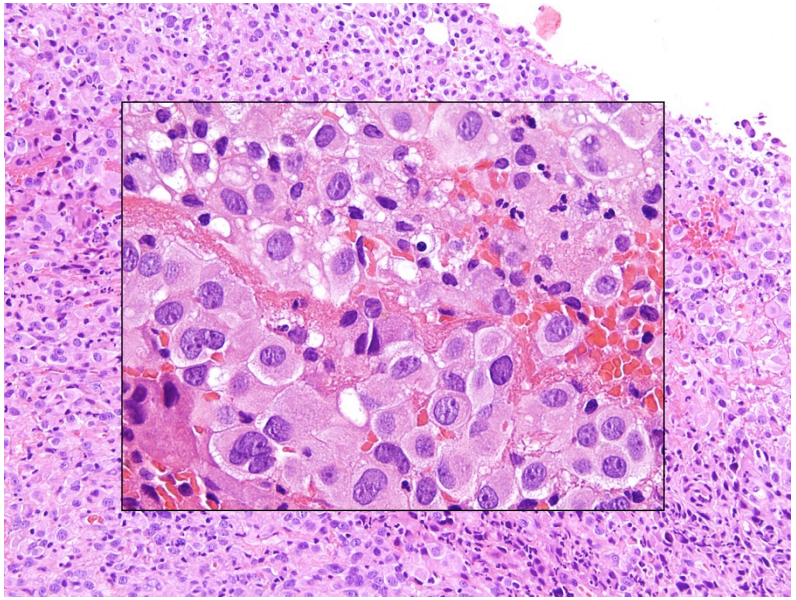

SONO DISPONIBILI MARCATORI DI MALIGNITA' PER LA DIAGNOSI DI MESOTELIOMA?

Marcatore	Iperplasia	Mesotelioma
Desmina	**> +**	**> -**
EMA	**> -**	**> +**
P53	**> -**	**> +**
GLUT1	**> -**	**> +**
IMP3	**> -**	**> +**
CD146	**> -**	**> +**
BAP1	**+**	**-**

p16 (analisi FISH)	Normale	Delezione omozigote

ALTERAZIONI CITOGENETICHE COMUNI NEL MESOTELIOMA

Delezioni: 1p, 3p, 4q, 4p, 6q, 9p, 11p, 13q, 22q, -22

Aggiunte: +5, +7, +20

Sandberg AA & Bridge JA Cancer Genet Cytogenet 2001, 127: 93-110

BAP1 **p16** **NF2**

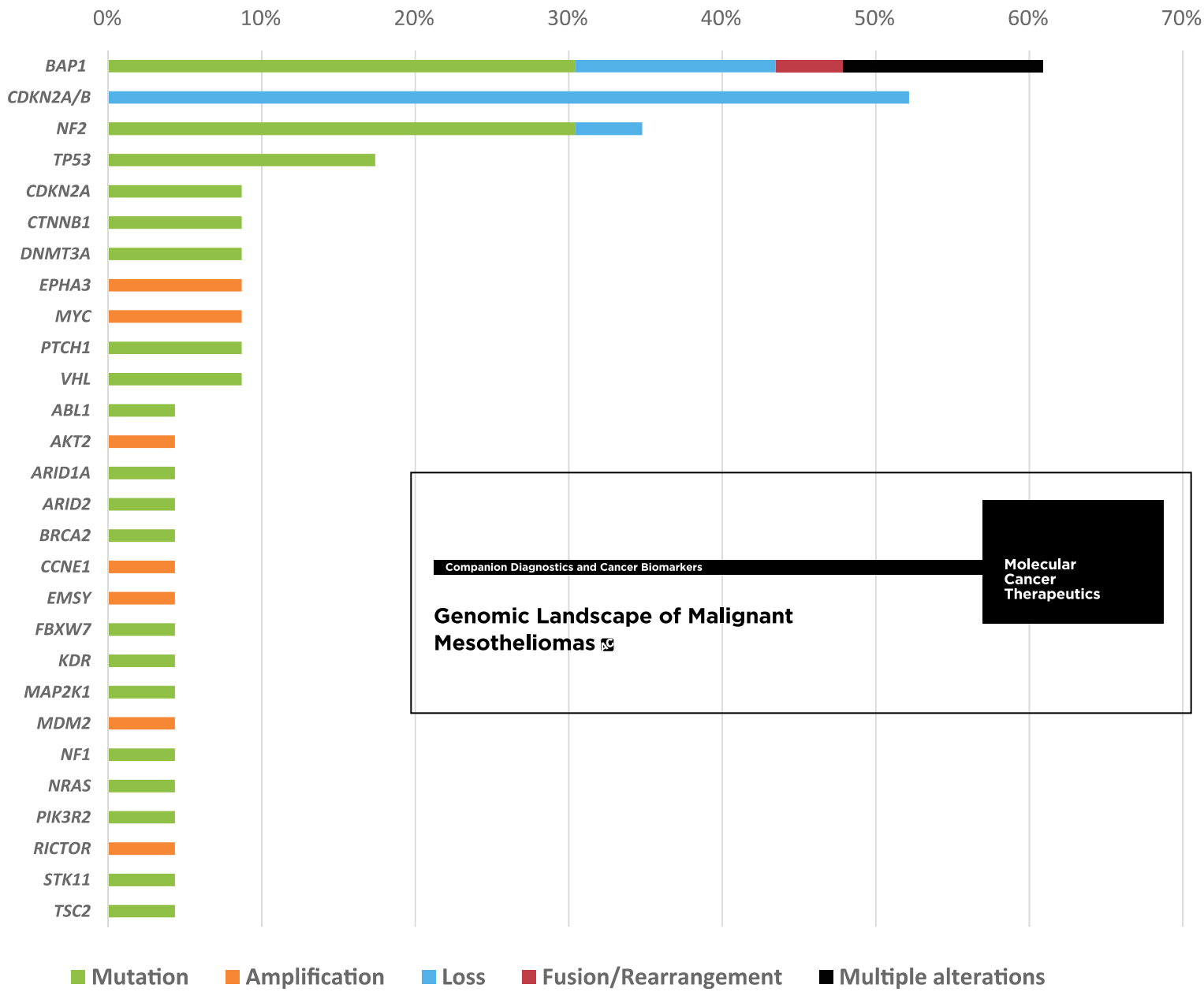

Figure 3.
Frequency and types of genetic aberrations (mutation, amplification, loss, fusion/rearrangement or multiple alteration) among pleural mesothelioma cases ($n = 23$).

BAP1 Immunohistochemistry and p16 FISH to Separate Benign From Malignant Mesothelial Proliferations

Brandon S. Sheffield, MD, Harry C. Hwang, MD,† Anna F. Lee, MD,‡ Kim Thompson, HT, ASCP, QIHC,† Stephanie Rodriguez, HT, MB, ASCP,† Christopher H. Tse, MBBS,† Allen M. Gown, MD,† and Andrew Churg, MD**

TABLE 2. Test Characteristics of p16 FISH, BAP1, EMA, p53, IMP3, and GLUT1 IHC

Marker	BAP1 IHC	p16 FISH	EMA	p53	IMP3*	GLUT1*
n	75	67	81	77	78	78
Benign	0/49	0/40	8/50	23/49	13/48	6/48
Malignant	7/26	14/27	10/31	16/28	16/30	18/30
Sensitivity (95% CI) (%)	27 (17-37)	52 (40-64)	32 (22-42)	57 (46-68)	53 (42-64)	60 (49-71)
Specificity (95% CI) (%)	100 (100-100)	100 (100-100)	84 (76-92)	53 (42-64)	73 (63-83)	88 (80-95)

TABLE 3. Test Characteristics of BAP1 IHC or p16 FISH Compared With Other Proposed Panels*

Panel	BAP1 IHC or p16 FISH	EMA or p53 IHC	EMA and p53 IHC	IMP3 and GLUT1 IHC†	p53 and IMP3 and GLUT1 IHC‡	EMA and IMP3 and GLUT1 IHC‡
n	61	76	76	78	73	76
Benign	0/37	24/48	6/48	2/48	2/45	1/46
Malignant	14/24	18/28	7/28	13/30	10/28	6/30
Sensitivity (95% CI) (%)	58 (46-71)	64 (54-75)	25 (15-35)	43 (32-54)	36 (25-47)	20 (11-29)
Specificity (95% CI) (%)	100 (100-100)	50 (39-61)	88 (80-95)	96 (91-100)	96 (91-100)	98 (95-100)

*Combinations designated as OR, required positivity of either marker. Combinations designated as AND, required positivity for both markers.
†Data from Lee et al.[9]
‡Data represents a synthesis from Lee et al[9] and this study.

BAP1 (BRCA1-associated protein 1) is a highly specific marker for differentiating mesothelioma from reactive mesothelial proliferations

Marta Cigognetti[1], Silvia Lonardi[1], Simona Fisogni[1], Piera Balzarini[1], Vilma Pellegrini[1], Andrea Tironi[1], Luisa Bercich[1], Mattia Bugatti[1], Giulio Rossi[2], Bruno Murer[3], Mattia Barbareschi[4], Silvia Giuliani[4], Alberto Cavazza[5], Gianpietro Marchetti[6], William Vermi[1] and Fabio Facchetti[1]

Table 1 BAP1 immunoreactivity in tissues biopsies

Diagnosis	*No. of cases*	*BAP1 loss (%)*
Normal mesothelium	11	0/11 (0)
Benign mesothelial tumor	12	0/12 (0)
Benign multicystic mesothelioma	3	0/3
Benign papillary mesothelioma	2	0/2
Adenomatoid tumor	7	0/7
Malignant mesothelioma	212	139/212 (66)
Epithelioid	184	128/184 (70)
Biphasic	15	9/15 (60)
Sarcomatoid	8	1/8 (13)
Desmoplastic	5	1/5 (20)
Reactive mesothelial proliferation	42	6/42 (14)
Simple	27	2/27 (7) [a]
Atypical	15	4/15 (27) [a]

[a]All BAP1-negative cases developed malignant mesothelioma.

BAP1 (BRCA1-associated protein 1) is a highly specific marker for differentiating mesothelioma from reactive mesothelial proliferations

Marta Cigognetti[1], Silvia Lonardi[1], Simona Fisogni[1], Piera Balzarini[1], Vilma Pellegrini[1], Andrea Tironi[1], Luisa Bercich[1], Mattia Bugatti[1], Giulio Rossi[2], Bruno Murer[3], Mattia Barbareschi[4], Silvia Giuliani[4], Alberto Cavazza[5], Gianpietro Marchetti[6], William Vermi[1] and Fabio Facchetti[1]

Table 3 BAP1 immunoreactivity in cytological and cell-block samples

Diagnosis	*No. of cases*	*BAP1 loss (%)*
Benign mesothelial reaction	17	0/17 (0)
Inflammatory	15	0/15 (0)
Lung adenocarcinoma	2	0/2 (0)
Malignant mesothelioma	45	29/45 (64)
Atypical mesothelial cells of indeterminate origin	8	6/8[a] (75)

[a]All BAP1-negative cases developed malignant mesothelioma.

The Separation of Benign and Malignant Mesothelial Proliferations

Andrew Churg, MD; Francoise Galateau-Salle, MD

(Arch Pathol Lab Med. 2012;136:1217–1226; doi10.5858/arpa.2012-0112-RA)

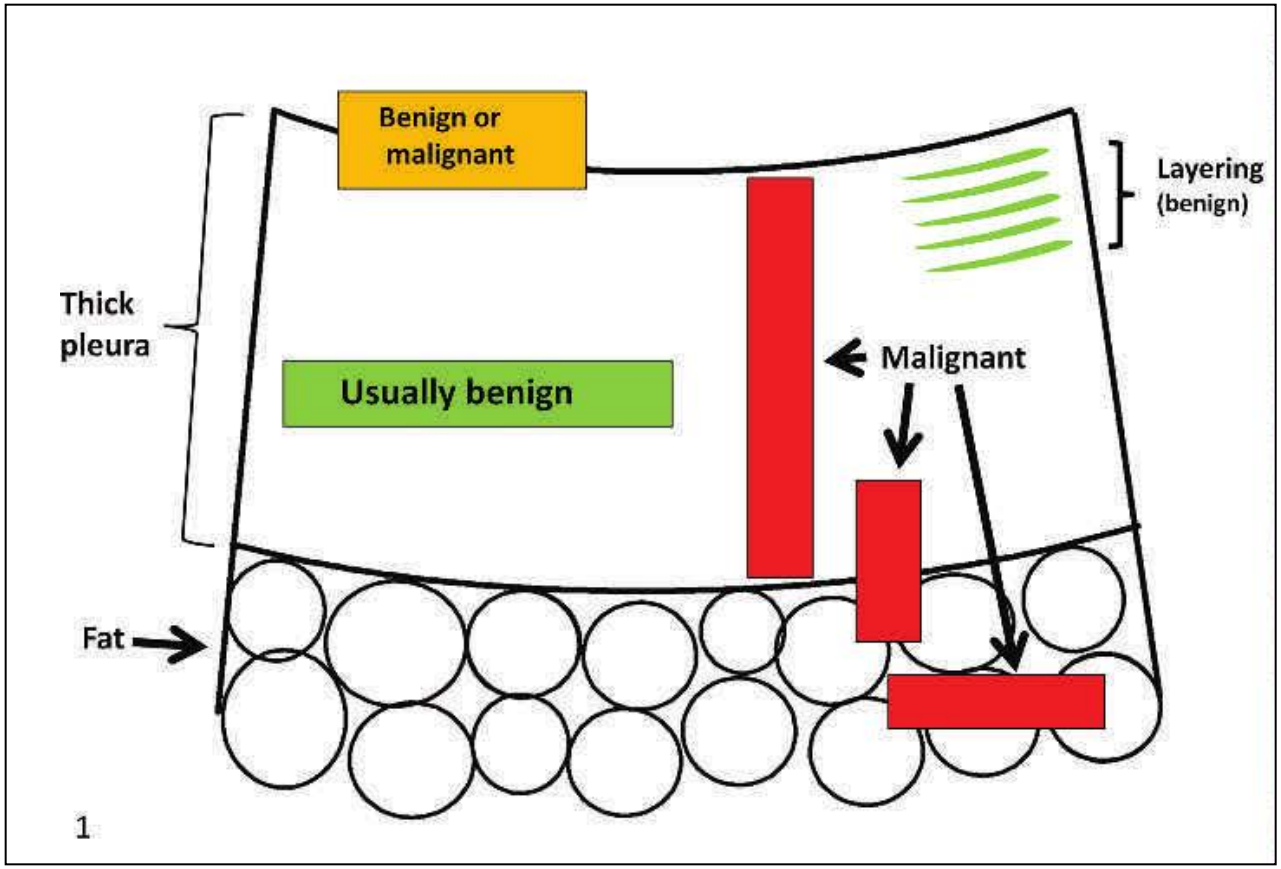

Table 2.02 Reactive atypical mesothelial hyperplasia versus malignant mesothelioma {458}

Histological features	Atypical mesothelial hyperplasia	Malignant mesothelioma
Major criteria		
Stromal invasion	Absent	Present (the deeper, the more definitive)
Cellularity	Confined to the pleural surface	Dense, with stromal reaction
Papillae	Simple, lined by single-cell layer	Complex, with cellular stratification
Growth pattern	Surface growth	Expansile nodules, complex and disorganized pattern
Zonation	Process becomes less cellular towards chest wall	No zonation of process, often more cellular away from effusion
Vascularity	Capillaries are perpendicular to the surface	Irregular and haphazard
Minor criteria		
Cytological atypia	Confined to areas of organizing effusion	Present in any area, but many cells are deceptively bland and relatively monotonous
Necrosis	Rare (necrosis may be within pleural exudate)	Necrosis of tumour area is usually a sign of malignancy
Mitoses	Mitoses may be plentiful	Many mesotheliomas show very few mitoses (but atypical mitoses favour malignancy)

New Markers for Separating Benign From Malignant Mesothelial Proliferations

Are We There Yet?

Andrew Churg, MD; Brandon S. Sheffield, MD; Francoise Galateau-Salle, MD

Arch Pathol Lab Med 2015

p16 analysis by FISH and immunohistochemical expression of BAP1 are at present the best markers for the purpose

Drawback: low sensitivity
Using both tests can improve sensitivity

Caution: MM can be p16 non-deleted and BAP1-positive

M, 76 aa, versamento pleurico

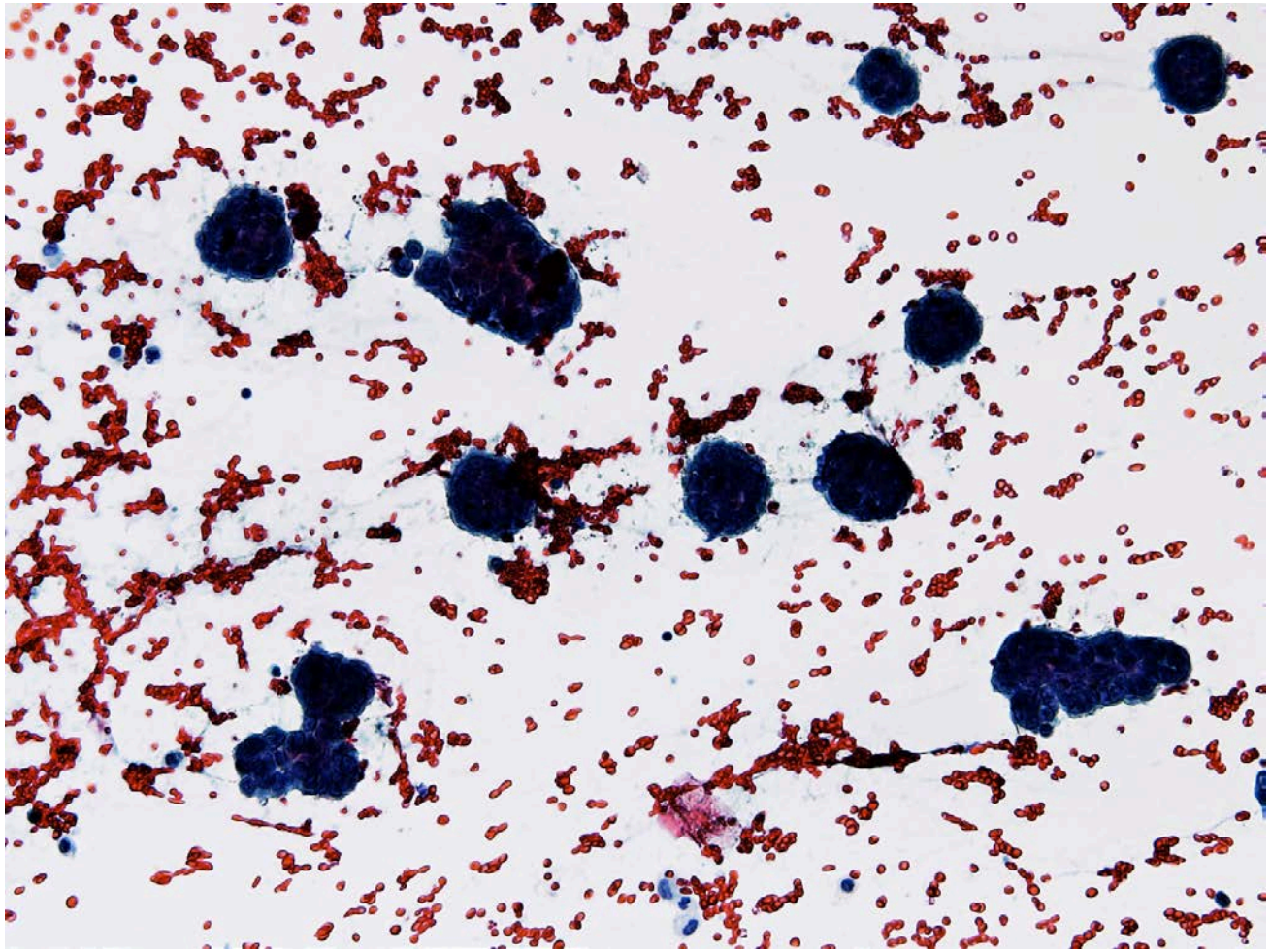

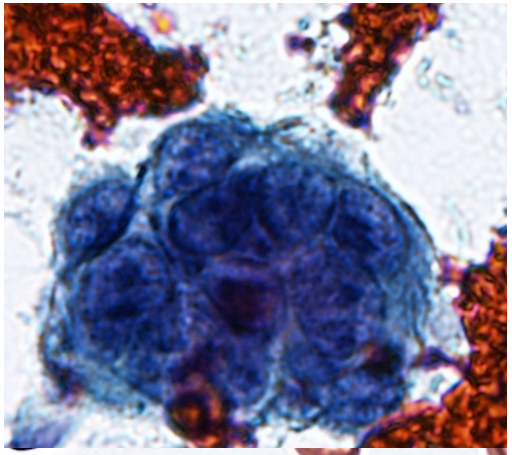

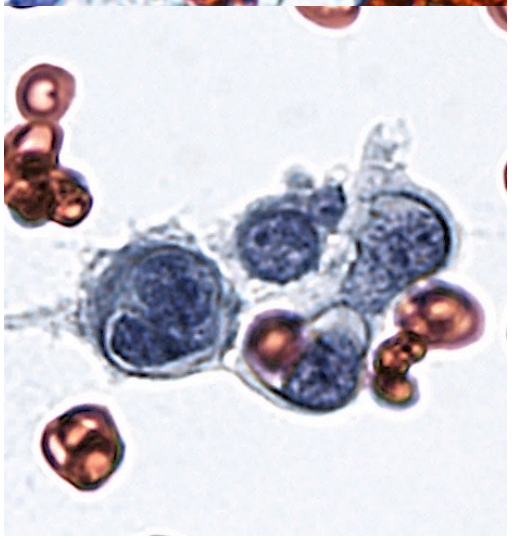

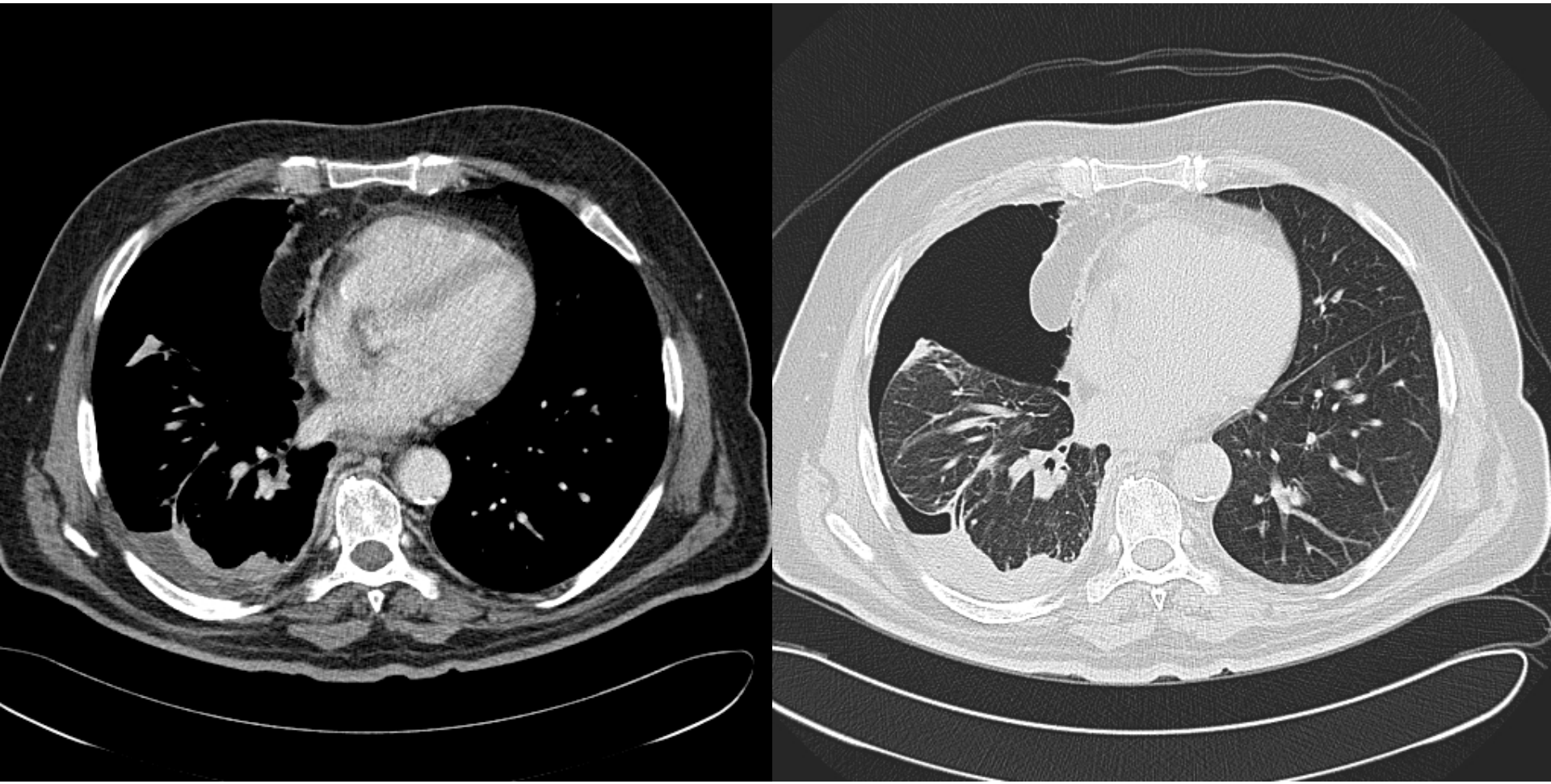

TC-torace (post-toracoscopia): pneumotorace, ispessimento pleura mediastinica, pleura sovra-diaframmatica, pleura viscerale